

## CASE REPORT

# Fenofibrate-induced hepatotoxicity: A case with a special feature that is different from those in the LiverTox database

Shizhan Ma PhD<sup>1</sup> | Shudong Liu MD<sup>2</sup>  | Qi Wang PharmD<sup>3</sup> | Lijuan Chen MMed<sup>2</sup> |  
Ping Yang MMed<sup>2</sup> | Huihuan Sun MMed<sup>2</sup>

<sup>1</sup>Department of Endocrinology and Metabolism, Shandong Provincial Hospital affiliated to Shandong First Medical University, Jinan, Shandong, China

<sup>2</sup>Department of Endocrinology, Shandong Rongjun General Hospital, Jinan, Shandong, China

<sup>3</sup>Department of Pharmacy, The Fifth People's Hospital of Jinan, Jinan, Shandong, China

## Correspondence

Shudong Liu, Department of Endocrinology, Shandong Rongjun General Hospital, 23 Jiefang Road, Jinan, Shandong 250013, China.

Email: lsd008@126.com

## Funding information

Shandong Provincial Natural Science Foundation, Grant/Award Number: ZR2019BH023; National Natural Science Foundation of China, Grant/Award Number: 81900716; Shandong Key R&D Program, Grant/Award Number: 2017GSF18129

## Abstract

**What is known and objective:** We report a special case of fenofibrate-induced acute severe DILI with sudden onset and rapid recovery, which is different from those in the LiverTox database.

**Case summary description:** The acute severe DILI occurred within only 4 days after fenofibrate initial treatment for hypertriglyceridemia. Liver enzyme levels eventually declined to normal within two weeks after the discontinuation of fenofibrate.

**What is new and Conclusion:** Early detection of elevated hepatic enzymes after fenofibrate initial treatment helps physicians to avoid delayed diagnosis and subsequent treatment.

## KEYWORDS

drug-induced liver injury, fenofibrate, hepatotoxicity, hypertriglyceridemia

## 1 | WHAT IS KNOWN AND OBJECTIVE

The LiverTox database (<https://livertox.nlm.nih.gov/index.html>) provides accessible information about the hepatotoxicity, mechanisms, clinical manifestation, outcomes and management of drug-induced liver injury (DILI).<sup>1</sup> DILI is difficult to diagnose and is becoming an interesting topic involving prescription and non-prescription medications, biological agents, Chinese herbs and extracts and dietary supplements.<sup>2-6</sup> Fenofibrate is a fibric acid derivative that has been widely used to clinically treat hypertriglyceridemia and dyslipidemia in patients for two decades. DILI associated with fenofibrate occurs very rarely (only 0.6% of patients).<sup>7</sup> In this paper, we present a special case of acute severe hepatocellular injury that is highly likely induced by fenofibrate after

therapy for a short period of time in a patient without primary or secondary liver disease.

## 2 | CASE SUMMARY DESCRIPTION

On 23 May 2018, a 65-year-old male was admitted to the Shandong Rongjun General Hospital due to fatigue and high blood glucose (13.7 mmol/L) for the second time. He had suffered from Type 2 diabetes mellitus for 6 years and had been treated with insulin aspart 50 injections for 10 months and with metformin hydrochloride sustained release tablets and acarbose for 6 years. The patient also had associated coronary heart disease that was treated with an intermittent therapy of suxiao jiu xin pill (a quick-acting heart pill) for

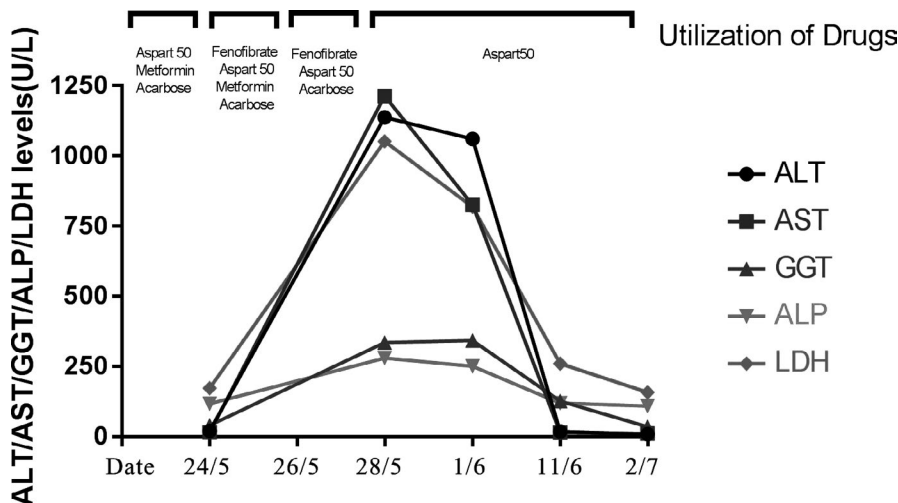
This is an open access article under the terms of the Creative Commons Attribution-NonCommercial License, which permits use, distribution and reproduction in any medium, provided the original work is properly cited and is not used for commercial purposes.

© 2019 The Authors. *Journal of Clinical Pharmacy and Therapeutics* published by John Wiley & Sons Ltd

**TABLE 1** The changes in laboratory values during hospitalization

Laboratory values	Date 1 (D/M/Y) 24/5/2018	Date 2 (D/M/Y) 28/5/2018	Date 3 (D/M/Y) 1/6/2018	Date 4 (D/M/Y) 11/6/2018	Date 5 (D/M/Y) 2/7/2018	Reference range
ALT (U/L)	20	1136.7	1060	18	8.4	9-50
AST (U/L)	15.3	1213.5	826	14	10.7	15-40
GGT (U/L)	39.6	335	342	127	35	10-60
ALP (U/L)	117.6	279.7	251	119	109.3	45-125
LDH (U/L)	172.2	1052	818	260	158	0-250
$\alpha$ -HDBH (U/L)	147.3	454	426	238	123.4	90-250
TP (g/L)	73.8	69.1	75.9	83	74	65-85
ALB (g/L)	43.5	40.1	39.9	41.1	43.2	40-55
TBIL ( $\mu$ mol/L)	11.7	32.6	29.2	7.8	11.7	5.1-19
DBIL ( $\mu$ mol/L)	5.2	23.8	18.2	3.3	4.1	1.7-6.8
TG (mmol/L)	6.74	1.98	2.12	3.84	5.51	0.56-1.71
CHO (mmol/L)	5.27	4.58	5.18	5.59	5.09	3.1-5.7
GLU (mmol/L)	11.6	10.9	11.3	9.2	6.3	3.8-6.1
Cr ( $\mu$ mol/L)	81.3	56.5	81.5	55.2	66.6	44-97

Abbreviations: ALB, albumin; ALP, alkaline phosphatase; ALT, alanine aminotransferase; AST, aspartate aminotransferase; CHO, total cholesterol; Cr, creatinine; D/Mo/Y, Day/Month/Year; DBIL, direct bilirubin; GGT, gamma-glutamyl transpeptidase; GLU, glucose; LDH, lactate dehydrogenase; TBIL, total bilirubin; TG, triglyceride; TP, total protein;  $\alpha$ -HDBH,  $\alpha$ -hydroxybutyric dehydrogenase.

**FIGURE 1** Utilization of drugs and hepatic enzymes changes during hospitalization

8 years. He was diagnosed with hypertriglyceridemia 2 years ago and took Rosuvastatin calcium for 1 month, which was ceased after hospital discharge. He had not been treated with fenofibrate since the diagnosis of hypertriglyceridemia, and there was no allergic history to any drug or food. A complete ultrasound of the abdomen was normal.

During the medical treatment period in our hospital, we continued administration of the previous hypoglycaemic agents (insulin aspart 50 injection, metformin hydrochloride sustained release tablets 500 mg orally b.i.d. and acarbose 50 mg orally t.i.d.). On admission, he did not feel chest distress and ceased his therapy with the suxiao jiu xin pill, which has been widely used to treat coronary heart disease without significant adverse reactions in China.<sup>8</sup> The

patient's laboratory results at the time of presentation are shown in Table 1. His laboratory values revealed apparent hypertriglyceridemia (6.74 mmol/L) on 24 May, so he started taking fenofibrate at a regular dose of 200 mg once daily to decrease the risk of pancreatitis and cardiovascular disease.<sup>9-11</sup> Before beginning fenofibrate treatment, he had normal serum liver enzymes and bilirubin. There was no family history of liver disease. On the morning of 26 May, metformin was added at a dose of 500 mg t.i.d. due to a high glucose level. Then, the patient felt epigastric pain, precordial pain and nausea. To exclude acute ischaemic cardiovascular events and other diseases, we conducted an electrocardiogram (ECG) and tested for myohemoglobin (MB), troponin I (Tnl), creatine kinase isoenzymes (CK-MB), ketone, amylpsin and creatinine, but these tests were all normal.

Adenosine cyclophosphate and pantoprazole sodium injection were administered to alleviate the symptoms. The pain was relieved but relapsed after breakfast. To rule out the suspicion of metformin, we stopped using metformin the same day and tested the ECG, MB, Tnl and CK-MB another day, but there were no abnormal findings. On 28 May, when the patient complained of epigastric discomfort and fatigue, liver enzymes were tested and found to be obviously elevated (Table 1; Figure 1). All potentially toxic drugs (fenofibrate, acarbose, adenosine cyclophosphate and pantoprazole sodium) were discontinued upon patient admission, so fenofibrate was the most probable cause of liver injury due to the chronological relationship. Studies are needed to further investigate the underlying causes of hepatitis, which presented all negative tests, including immunoglobulins M to hepatitis A virus and hepatitis E virus, antibodies to hepatitis B virus and hepatitis C virus, antibodies to human immunodeficiency virus (HIV1/2), cytomegalovirus DNA, Epstein-Barr virus DNA, antinuclear antibodies, anti-smooth muscle antibodies, antimitochondrial antibodies, serum tumour markers and anti-liver kidney antibodies. Liver enzyme levels eventually declined to normal with diammonium glycyrrhizinate and reduced glutathione treatments within 2 weeks after the discontinuation of fenofibrate (Table 1; Figure 1).

Upon admission, the patient showed normal hepatic enzymes, and there was no previously known liver disease or alcoholism history. The patient was found to be free of autoimmune hepatitis, viral hepatitis and infectious hepatitis. None of his medication histories, such as *suxiao jiu*xin pill, metformin and acarbose, are known to result in a high elevation of liver enzymes. After excluding all the suspected factors, we considered the diagnosis of DILI. Fenofibrate was the most likely medication to be associated with DILI because it was a new medication added to treat hypertriglyceridemia of the patient, regardless of serum drug concentrations and liver biopsy examination. The RUCAM (Roussel Uclaf Causality Assessment Method) score of ten suggested a highly probable association between hepatocellular injury and fenofibrate ( $R = 10$ ), which was defined using  $ALT > 5N$  ( $N$ , upper limit of normal) or  $ALP > 2N$  and  $R$  (Ratio,  $ALT/ALP$ )  $\geq 5$ .<sup>12</sup>

Fenofibrate is a fibric acid derivative that is well tolerated and used mainly to treat hypertriglyceridemia and hypercholesterolaemia for cardioprotection.<sup>13-16</sup> A dose of 43 to 130 mg orally once daily is the initial dose in adults and can be adjusted to 300 mg after dinner once daily according to the manufacturer's instructions. The common adverse effects of fenofibrate reported in liver injury patients include gastrointestinal upset, rash, myopathy, fever, rhabdomyolysis and renal failure<sup>17-23</sup>; acute DILI induced by fenofibrate is rare (0.6%) and usually asymptomatic, transient and mild, but a very severe case could result in liver transplantation treatment or death.<sup>7,17,18,20</sup> The latency to onset is variable, ranging from 2 weeks to even 2 years of fenofibrate treatment.<sup>1,7,24</sup> We reported that the epigastric pain of the patient occurred only after taking fenofibrate for 2 days, and this pain may be an early symptom associated with the onset of acute ischaemic cardiovascular events or the side effect of metformin. Of course, it is difficult to differentiate whether this condition is a side effect of metformin

or an early clinical manifestation of hepatitis. However, the hepatic enzymes of the patient were associated with significantly severe hepatitis symptoms with a rapid elevation to above 30 $\times$  the upper limit of normal at 4 days after fenofibrate initial treatment. In most cases, documents from the online 'LiverTox' database demonstrated that elevated liver enzymes eventually declined to normal within 2 to 12 months after the discontinuation of fenofibrate.<sup>1</sup> Surprisingly, we found that the hypertriglyceridemia of the case was improved despite the short period of time of fenofibrate treatment; however, the plasma triglyceride concentrations re-elevated to previous levels after fenofibrate discontinuation in a one-month follow-up period (Table 1; Figure 1). On the other hand, the clinical symptoms and liver injury of the case rapidly recovered within two weeks of the withdrawal of fenofibrate, which was also helpful in confirming the diagnosis of fenofibrate-induced DILI.

The mechanism of DILI associated with fenofibrate is unclear thus far. The triglyceride-reducing effect of fenofibrate is thought to be mediated by the activation of the peroxisome proliferator-activated receptor  $\alpha$  (PPAR $\alpha$ ) and lipoprotein lipase, which regulates the gene expression of enzymes involved in fatty acid oxidation and triglyceride clearance.<sup>25</sup> Furthermore, fenofibrate, a PPAR $\alpha$  agonist, increases plasma and hepatic transaminase activities in parallel with increases in both ALT and AST gene expression via the PPAR $\alpha$  pathway.<sup>26,27</sup> This phenomenon was non-pathological and not considered to be a consequence of hepatotoxicity from fenofibrate.<sup>17,26-28</sup> Obviously, the markedly high elevation of liver enzymes inducing hepatotoxicity is not an expected response to treatment and should be avoided. Inflammatory, immunological factors and genetic heterogeneity appear to be involved in the onset and progression of fenofibrate-induced DILI, and one recent study demonstrated that HLA-A\*33:01 may have potent effects on fenofibrate-induced DILI.<sup>7,22,29-31</sup> Several clinical studies have reported that some DILI case reports were not attributed to fenofibrates.<sup>3,23,32</sup> Li et al demonstrated that fenofibrate improved mitochondrial fatty acid  $\beta$ -oxidation and recovered cholestatic liver injury.<sup>33</sup> The relationship between DILI and fenofibrate is controversial because various confounding factors, such as multiple drug interactions and idiosyncratic effects, often coexist, so the direct causative relation is difficult to confirm<sup>34</sup>; most DILI diagnoses are dependent on the exclusion of other potential agents. More studies and methodologies are needed for further causality assessments in the future.

### 3 | WHAT IS NEW AND CONCLUSION

We report a case of fenofibrate-induced acute severe DILI with sudden onset and rapid recovery. As suggested, hepatic enzymes must be measured at least two weeks or even earlier after initial fenofibrate treatment followed by monitoring every 3 months within the first year of therapy.<sup>18</sup> We suggest that early detection of elevation of hepatic enzymes after fenofibrate initial treatment is important to avoid delayed diagnosis and subsequent treatment.

## ACKNOWLEDGMENTS

This work was funded by the project ZR2019BH023 supported by Shandong Provincial Natural Science Foundation.

## CONFLICT OF INTEREST

All authors declare that they have no conflicts of interest.

## ORCID

Shudong Liu  <https://orcid.org/0000-0002-8382-5328>

## REFERENCES

1. Hoofnagle JH, Serrano J, Knoben JE, Navarro VJ. LiverTox: a website on drug-induced liver injury. *Hepatology*. 2013;57(3):873-874.
2. Rangnekar AS, Fontana RJ. An update on drug induced liver injury. *Minerva Gastroenterol Dietol*. 2011;57(2):213-229.
3. Bjornsson ES, Bergmann OM, Bjornsson HK, Kvaran RB, Olafsson S. Incidence, presentation, and outcomes in patients with drug-induced liver injury in the general population of Iceland. *Gastroenterology*. 2013;144(7):1419-1425, 1425 e1411-1413; quiz e1419-1420.
4. Vega M, Verma M, Beswick D, et al. The incidence of drug- and herbal and dietary supplement-induced liver injury: preliminary findings from gastroenterologist-based surveillance in the population of the state of Delaware. *Drug Saf*. 2017;40(9):783-787.
5. Bjornsson ES. Drug-induced liver injury: an overview over the most critical compounds. *Arch Toxicol*. 2015;89(3):327-334.
6. Licata A. Adverse drug reactions and organ damage: The liver. *Eur J Intern Med*. 2016;28:9-16.
7. Ahmad J, Odin JA, Hayashi PH, et al. Identification and characterization of fenofibrate-induced liver injury. *Dig Dis Sci*. 2017;62(12):3596-3604.
8. Ren L, Wang J, Feng L, Wang S, Li J. Efficacy of suxiao jiuixin pill on coronary heart disease: a meta-analysis of randomized controlled trials. *Evid Based Complement Alternat Med*. 2018;2018:9745804.
9. Elam M, Lovato L, Ginsberg H. The ACCORD-Lipid study: implications for treatment of dyslipidemia in Type 2 diabetes mellitus. *Clin Lipidol*. 2011;6(1):9-20.
10. Cholesterol N. Education program expert panel on detection e, treatment of high blood cholesterol in A. Third Report of the national cholesterol education program (NCEP) expert panel on detection, evaluation, and treatment of high blood cholesterol in adults (Adult Treatment Panel III) final report. *Circulation*. 2002;106(25):3143-3421.
11. Berglund L, Brunzell JD, Goldberg AC, et al. Evaluation and treatment of hypertriglyceridemia: an Endocrine Society clinical practice guideline. *J Clin Endocrinol Metab*. 2012;97(9):2969-2989.
12. Danan G, Teschke R. RUCAM in drug and herb induced liver injury: the update. *Int J Mol Sci*. 2015;17(1):14.
13. d'Emden MC, Jenkins AJ, Li L, et al. Favourable effects of fenofibrate on lipids and cardiovascular disease in women with type 2 diabetes: results from the fenofibrate intervention and event lowering in diabetes (FIELD) study. *Diabetologia*. 2014;57(11):2296-2303.
14. Scott R, O'Brien R, Fulcher G, et al. Effects of fenofibrate treatment on cardiovascular disease risk in 9,795 individuals with type 2 diabetes and various components of the metabolic syndrome: the fenofibrate intervention and event lowering in diabetes (FIELD) study. *Diabetes Care*. 2009;32(3):493-498.
15. Burgess DC, Hunt D, Li L, et al. Incidence and predictors of silent myocardial infarction in type 2 diabetes and the effect of fenofibrate: an analysis from the fenofibrate intervention and event lowering in diabetes (FIELD) study. *Eur Heart J*. 2010;31(1):92-99.
16. Keating GM. Fenofibrate: a review of its lipid-modifying effects in dyslipidemia and its vascular effects in type 2 diabetes mellitus. *Am J Cardiovasc Drugs*. 2011;11(4):227-247.
17. Dohmen K, Wen CY, Nagaoka S, et al. Fenofibrate-induced liver injury. *World J Gastroenterol*. 2005;11(48):7702-7703.
18. Ho CY, Kuo TH, Chen TS, Tsay SH, Chang FY, Lee SD. Fenofibrate-induced acute cholestatic hepatitis. *J Chin Med Assoc*. 2004;67(5):245-247.
19. Kiskac M, Zorlu M, Cakirca M, et al. A case of rhabdomyolysis complicated with acute renal failure after resumption of fenofibrate therapy: a first report. *Indian J Pharmacol*. 2013;45(3):305-306.
20. Hajdu D, Aiglova K, Vinklerova I, Urbanek K. Acute cholestatic hepatitis induced by fenofibrate. *J Clin Pharm Ther*. 2009;34(5):599-602.
21. Davis TME, Ting R, Best JD, et al. Effects of fenofibrate on renal function in patients with type 2 diabetes mellitus: the fenofibrate intervention and event lowering in diabetes (FIELD) Study. *Diabetologia*. 2011;54(2):280-290.
22. Skop V, Trnovska J, Oliyarnyk O, et al. Hepatotoxic effects of fenofibrate in spontaneously hypertensive rats expressing human C-reactive protein. *Physiol Res*. 2016;65(6):891-899.
23. Hedrington MS, Davis SN. Peroxisome proliferator-activated receptor alpha-mediated drug toxicity in the liver. *Expert Opin Drug Metab Toxicol*. 2018;14(7):671-677.
24. Rigal J, Furet Y, Autret E, Breteau M. Severe mixed hepatitis caused by fenofibrate? A review of the literature apropos of a case. *Rev Med Interne*. 1989;10(1):65-67.
25. Rosenson RS. Fenofibrate: treatment of hyperlipidemia and beyond. *Expert Rev Cardiovasc Ther*. 2008;6(10):1319-1330.
26. Kobayashi A, Suzuki Y, Kuno H, Sugai S, Sakakibara H, Shimoi K. Effects of fenofibrate on plasma and hepatic transaminase activities and hepatic transaminase gene expression in rats. *J Toxicol Sci*. 2009;34(4):377-387.
27. Edgar AD, Tomkiewicz C, Costet P, et al. Fenofibrate modifies transaminase gene expression via a peroxisome proliferator activated receptor alpha-dependent pathway. *Toxicol Lett*. 1998;98(1-2):13-23.
28. Thulin P, Rafter I, Stockling K, et al. PPARalpha regulates the hepatotoxic biomarker alanine aminotransferase (ALT1) gene expression in human hepatocytes. *Toxicol Appl Pharmacol*. 2008;231(1):1-9.
29. Nicoletti P, Aithal GP, Bjornsson ES, et al. Association of liver injury from specific drugs, or groups of drugs, with polymorphisms in hla and other genes in a genome-wide association study. *Gastroenterology*. 2017;152(5):1078-1089.
30. Okamoto H, Kamatani N. Successful treatment with fenofibrate of autoimmune hepatitis in a patient with rheumatoid arthritis. *Scand J Rheumatol*. 2007;36(3):235-236.
31. Corpechot C. Primary biliary cirrhosis and bile acids. *Clin Res Hepatol Gastroenterol*. 2012;36(suppl 1):S13-20.
32. Reuben A, Koch DG, Lee WM, Acute Liver Failure Study G. Drug-induced acute liver failure: results of a U.S. multicenter, prospective study. *Hepatology*. 2010;52(6):2065-2076.
33. Zhao Q, Yang R, Wang J, Hu DD, Li F. PPARalpha activation protects against cholestatic liver injury. *Sci Rep*. 2017;7(1):9967.
34. Kim SH, Naisbitt DJ. Update on advances in research on idiosyncratic drug-induced liver injury. *Allergy Asthma Immunol Res*. 2016;8(1):3-11.

**How to cite this article:** Ma S, Liu S, Wang Q, Chen L, Yang P, Sun H. Fenofibrate-induced hepatotoxicity: A case with a special feature that is different from those in the LiverTox database. *J Clin Pharm Ther*. 2019;00:1-4. <https://doi.org/10.1111/jcpt.13042>